

# The Carolina Bridge: A Novel Interim All-Porcelain Bonded Prosthesis

HARALD O. HEYMANN, DDS, MED\*

## ABSTRACT

Numerous bonded bridge designs have been advocated over the years for the temporary or permanent replacement of missing teeth. Both metal and all-porcelain designs of bonded bridges have been advocated, with varying degrees of success. However, all of these designs involve some degree of tooth preparation, making them irreversible in nature. The Carolina bridge, a novel all-porcelain bonded pontic, requires no significant tooth preparation, making it an outstanding option as an interim prosthesis. The key to success is the availability of adequate surface area interproximally to ensure optimally strong resin composite connectors.

## CLINICAL SIGNIFICANCE

This article describes the indications, contraindications, and clinical technique for the placement of an ultraconservative all-porcelain bonded bridge for the interim replacement of single incisors.

*(J Esthet Restor Dent 18:81–92, 2006)*

With the advent of adhesive dentistry, many approaches have been advocated for the conservative replacement of missing anterior teeth. A myriad of bonded bridge designs have been introduced over the years. An early version of a bonded bridge was the Rochette-type bridge.<sup>1,2</sup> This design uses countersunk holes in the metal retaining wings for retention of the bridge to the lingual surfaces of the adjacent teeth via a resin composite cement.

Subsequently, Maryland bridges were introduced that also incorporated metal retaining wings.<sup>3,4</sup>

Etched metal surfaces afford strong micromechanical bonds of the metal retaining wings to the adjacent abutment teeth. Soon thereafter, another version of the Maryland bridge, the adhesion bridge, was introduced and has been widely used.<sup>5,6</sup> This design relies upon various surface treatments (eg, sandblasting, silicoating) of the metal wings along with chemically adhesive cement formulations (eg, 4-META) to facilitate strong resin-to-tooth bonds.

Additionally, tooth-colored versions of the Maryland bridge have been advocated. An early form of this

type of bridge was the all-porcelain veneer bridge.<sup>7–9</sup> This design used facial or lingual porcelain veneers bonded to adjacent abutment teeth to retain a porcelain pontic. However, this type of bridge was found to afford poor resistance to fracture and unnecessarily covered otherwise intact, healthy tooth structure on abutment teeth.<sup>10,11</sup>

More recently, other tooth-colored bonded bridges made from processed resin or high-strength ceramics have been advocated. A variant of this type of processed resin bonded bridge, the Encore bridge (da Vinci Dental Studios,

\*Professor, Department of Operative Dentistry, UNC School of Dentistry, Chapel Hill, NC, USA

Woodland Hills, CA, USA), consists of a pontic used in conjunction with a facially bonded porcelain veneer.<sup>12,13</sup> Tooth-colored Maryland bridges also have been noted in the literature made from In-Ceram (Vita Zahnfabrik, Bad Säckingen, Germany).<sup>14-16</sup> However, owing to the fact that processed resin possesses little potential for chemical adhesion, surface treatments, such as sandblasting, must be used to achieve mechanical adhesion to abutment teeth. Similarly, mechanical adhesion is difficult to attain with In-Ceram; however, silicoating does seem to improve adhesion with In-Ceram to some degree. Regardless, the incorporation of proximal grooves is recommended to improve macromechanical retention of this bridge design.<sup>16</sup>

All of these bridge types have been used with varying degrees of success, and when properly made, some can provide excellent bond strengths. However, all of these bridge designs share one significant disadvantage: they all require some degree of tooth preparation and, as such, are irreversible in nature.

More conservative options for anterior bonded bridges also have been introduced over the years that, by contrast to the bridges noted above, do not require any appreciable tooth preparation. These include bonded denture tooth bridges,

extracted natural tooth pontics, and custom resin composite pontics.<sup>17-19</sup> All of these bonded bridge designs are exceptionally conservative and rely on resin composite connectors between the pontic and the abutment teeth for retention. Of course, a favorable occlusion and sufficient surface area on the adjacent abutment teeth must be present to ensure optimal success with these conservative bridge types. Also, because these types of bonded bridges do not provide the bond strengths of conventional bridges and probably are not as strong as porcelain-fused-to-metal Maryland-type bridges, they are typically advocated as interim or provisional restorations.

Despite the more provisional nature of these bridges, they have been widely used with success for the replacement of single missing incisors in patients for whom a more permanent prosthesis is neither practical nor affordable. This is particularly true for extracted natural tooth pontics. In many cases involving elderly patients with compromised periodontal or medical health or limited financial means, extracted natural tooth pontics afford a practical and beneficial alternative to more traditional prostheses. Moreover, owing to the simplicity with which the resin composite connectors can be placed, these bridges are easy to repair and maintain.

#### THE CAROLINA BRIDGE

The purpose of this article is to review an alternative approach for the replacement of single missing incisors using a custom-fabricated all-porcelain bonded pontic, the Carolina bridge. This name was coined by Drake Precision Dental Lab of Charlotte, NC, USA, in the late 1990s. First used by the author in 1987, this simple design consists of a custom-made all-porcelain pontic with an etched proximal surface that is bonded to the adjacent abutment teeth using resin composite connectors (Figure 1).<sup>20</sup>

The primary qualities of this type of bonded bridge include ease of placement, esthetic vitality (no metal substructure), ease of connector repair, and a totally reversible nature. As with all bonded bridges, the primary keys to success include the availability of adequate surface area for bonding, favorable occlusion, and periodontally sound and stable abutment teeth.

#### INDICATIONS

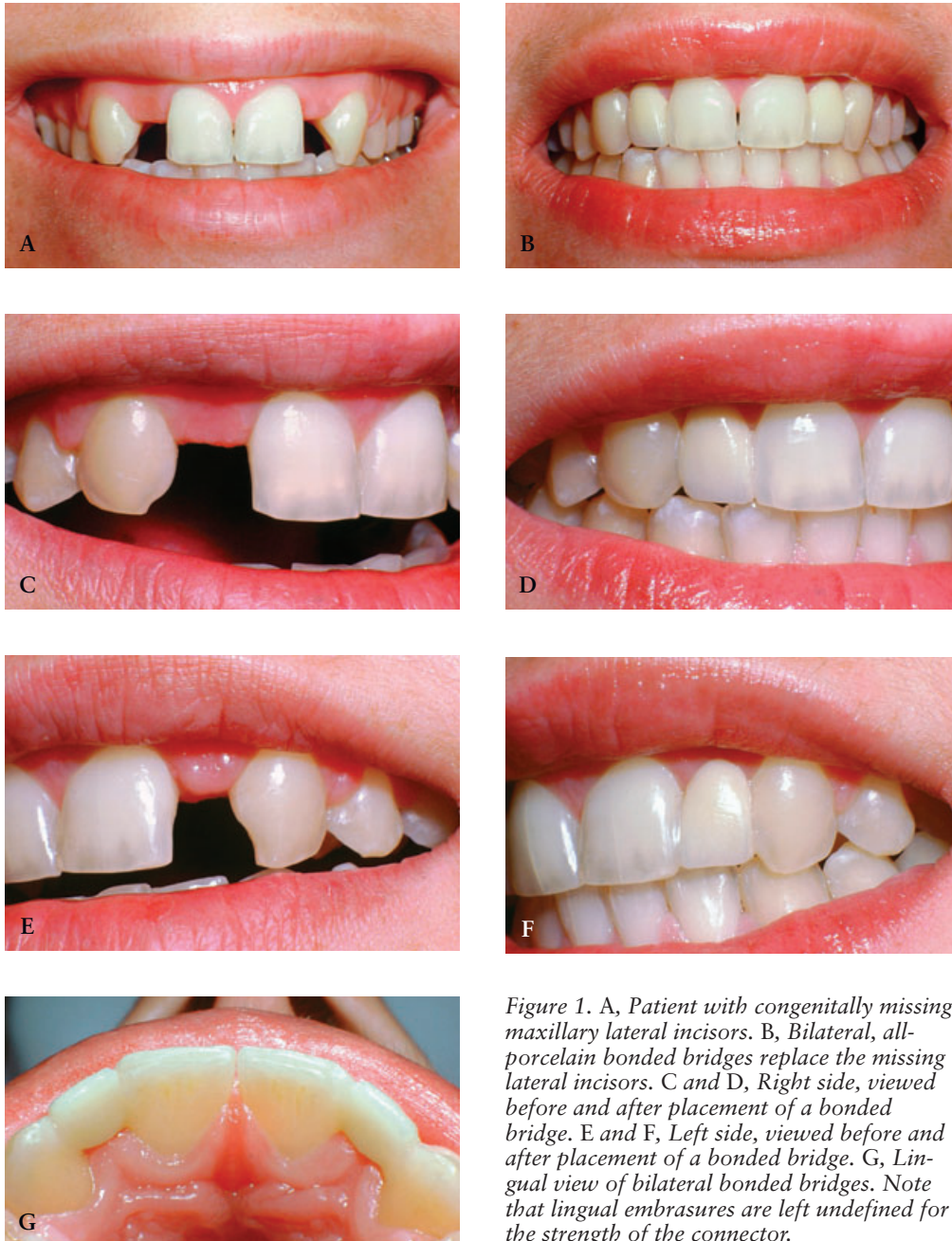
Patients best suited for an all-porcelain bonded Carolina bridge are young adolescents with missing maxillary incisors. Adolescent patients with congenitally missing maxillary lateral incisors are frequently ideal candidates (Figure 2).

Although the best long-term solution frequently is the placement of

a dental implant, patient age often precludes this option in adolescents. Heretofore the only reversible option for interim incisor

replacement in adolescent patients has been a “flipper-type” temporary prosthesis or a denture tooth attached to a Hawley retainer.

Both options are not very hygienic, with tissue inflammation and papillary hyperplasia being common resultant sequelae.



*Figure 1. A, Patient with congenitally missing maxillary lateral incisors. B, Bilateral, all-porcelain bonded bridges replace the missing lateral incisors. C and D, Right side, viewed before and after placement of a bonded bridge. E and F, Left side, viewed before and after placement of a bonded bridge. G, Lingual view of bilateral bonded bridges. Note that lingual embrasures are left undefined for the strength of the connector.*

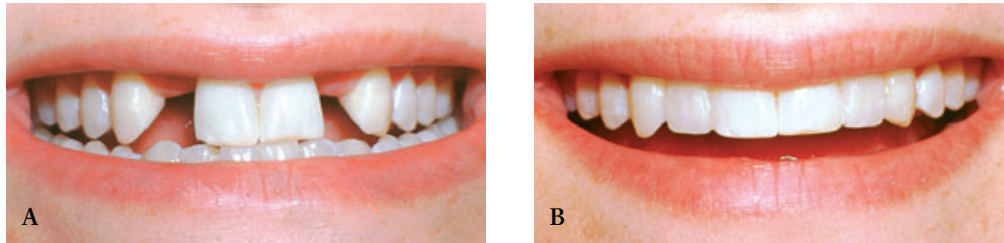


Figure 2. A, Patient with congenitally missing maxillary lateral incisors. B, Bilateral, all-porcelain bonded bridges replace the missing lateral incisors.

In these cases, an all-porcelain bonded pontic is an excellent interim prosthesis because of its totally reversible nature. Unlike Maryland-type bridges and other bonded bridges involving some degree of tooth preparation, the all-porcelain bonded pontic, or Carolina bridge, requires no significant tooth preparation, making it entirely reversible. The abutment teeth can be returned to their original virgin condition simply through removal of the bonded pontic and the resin composite connectors. Subsequent treatment with an implant is not precluded.

As noted above, this alternative is particularly well suited as an interim prosthesis for adolescent patients with congenitally missing lateral incisors. However, where indicated, the Carolina bridge also can be used as a restorative alternative in cases for which a more permanent fixed prosthesis is neither practical nor affordable owing to the patient's age, medical condition, or economic status (Figures 3 and 4). Additionally, patients with missing lateral incisors and in whom the

remaining edentulous space is too small for an implant often are excellent candidates for an all-porcelain bonded pontic of this type. By slightly lapping the adjacent teeth, an esthetically acceptable prosthesis can be obtained.

Ideally, patients should exhibit an occlusal relationship with little vertical overlap. Clearly, patients who exhibit an end-to-end or slight open-bite anterior occlusal relationship are well suited for this type of bridge. Adolescent, post-orthodontic treatment patients often fall into this ideal category.

In all cases, patients must be cautioned as part of informed consent that the Carolina bridge does not possess the strength of a conventional prosthesis and therefore must be used with caution to prevent dislodgment. However, properly done, this type of bonded all-porcelain pontic can provide an excellent interim esthetic alternative.

#### CONTRAINDICATIONS

Carolina bridges are not indicated for the replacement of posterior

teeth or canines because of the degree of occlusal stress encountered in these areas. Additionally, patients exhibiting a deep-bite anterior occlusal relationship and/or evidence of bruxism or clenching involving the anticipated area to be treated are contraindicated.

Most importantly, abutment teeth must exhibit sufficient incisogingival height to ensure adequate surface area for bonding. Short teeth are contraindicated as abutments. The absolute key to success is the availability of adequate surface area for bonding. This fact cannot be overemphasized. Accordingly, the abutment teeth must be sufficiently long to provide the surface area needed for successful bonding.

In most cases, a minimum incisogingival height of 5 mm is needed along the proximal surface to ensure adequate bonding. To achieve this requisite condition it is sometimes necessary to expose more of the clinical crown through a surgical crown lengthening procedure. In adolescent patients, this type of procedure is generally not undertaken

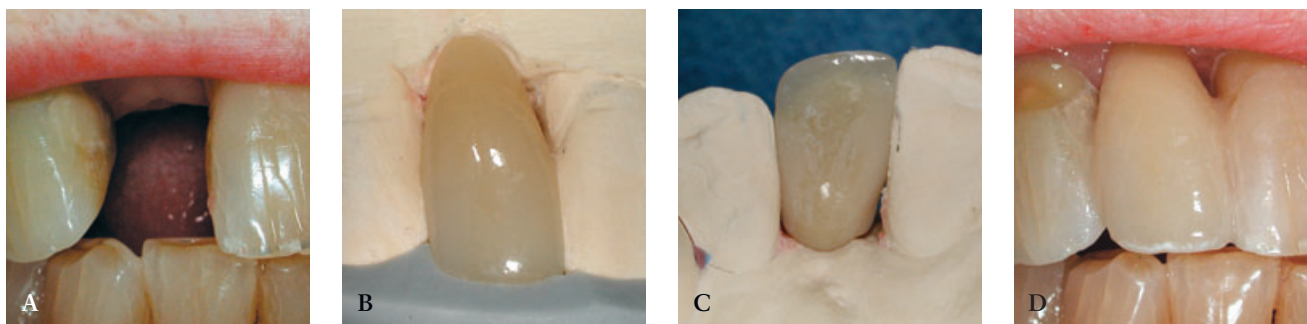


Figure 3. A, Elderly patient with a missing maxillary lateral incisor. B, Porcelain pontic viewed on a model with a polyvinyl-siloxane index. C, Lingual view of a pontic on a model. D, All-porcelain bonded bridge viewed after placement. Note the long incisogingival length of connectors, which are essential to success.

until approximately age 15 years. A need for crown lengthening of abutment teeth is not uncommonly seen in young patients who have recently completed orthodontic treatment and whose teeth exhibit a buildup of redundant or hyperplastic tissue along proximal surfaces.

Patients also must possess sound abutment teeth with small or no proximal restorations and with no crowns. Teeth with large Class III or IV restorations are contraindicated as abutment teeth, as are teeth with crowns. Abutment teeth also must be sound periodontally, with little mobility.

#### ADVANTAGES OF THE CAROLINA BRIDGE

Carolina bridges offer many advantages over metal “winged” pontic-type bridges. Properly done, Maryland-type bridges (and adhesion bridges) can serve as superb conservative prostheses for replacement of posterior missing teeth because, generally, sufficient surface area is available for the incorporation of a number of retention features. These include occlusal rests, inlay components, wrap-around retainer designs, and internally prepared slots or grooves. In a well-designed posterior Maryland bridge, the design of the prosthesis

effectively protects the bond, often rendering a highly successful result.

However, when used for replacement of missing anterior teeth, Maryland-type bridges experience more problems owing to the limited amount of proximal surface area in which to incorporate adequate retention features, such as proximal grooves. Certainly, success can be achieved with anterior Maryland bridges in some cases, but the potential for problems is much greater.

The design of the Carolina bridge avoids many of the problems associated with Maryland bridges,

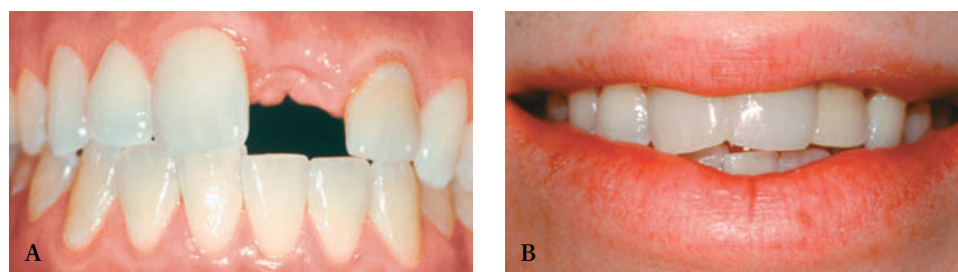


Figure 4. A, Patient with a traumatically missing maxillary central incisor. B, An all-porcelain bonded bridge replaces the missing central incisor.

including adhesion bridges. First, as noted earlier, no definitive preparation of the adjacent abutment teeth is required, making this approach totally reversible. Second, the all-porcelain Carolina bridge is highly esthetic owing to the absence of a metal substructure. Esthetic vitality from optimal light penetration is superb. By contrast, Maryland bridges are notoriously unesthetic because of the graying potential created by the metal wings, particularly in translucent abutment teeth. Moreover, the metal framework in the pontic area of an anterior Maryland bridge often limits the thickness of porcelain needed to achieve excellent esthetic vitality.

Also, all-porcelain pontics, such as the Carolina bridge, often can be used when tooth anatomy precludes or restricts the preparation and placement of a Maryland-type bridge. For example, long, pointed canines with proximal surfaces exhibiting little incisogingival height often lack adequate surface area for the placement of retention grooves (see Figure 1E and F). Also, anterior teeth that are notably thin faciolingually often still can be treated with an all-porcelain Carolina bridge in many cases in which a Maryland bridge would be an esthetic failure.

Third, the proximal resin composite retaining connectors of all-porcelain Carolina bridges are easily repaired.

By contrast, if one wing of a Maryland bridge becomes loose, it is most difficult to remove the bridge without damage to the prosthesis or the abutment tooth. Worse yet, if the loose wing goes undetected, caries can develop that requires more extensive restoration of the abutment tooth, often precluding re-treatment with a new Maryland bridge. In another worst-case scenario, if food impaction occurs between the loose metal retaining wing and the underlying tooth, the tooth can actually be displaced facially, requiring orthodontic correction. All of these problems are avoided with the all-porcelain Carolina bridge.

#### CLINICAL TECHNIQUE

In the case used to illustrate this technique, an adolescent patient, age 14 years, presented with a missing maxillary right lateral incisor (Figure 5A). The patient lost the clinical crown owing to trauma. It was determined by a team consisting of a periodontist, an orthodontist, an endodontist, and a restorative dentist that a dental implant ultimately will be the best treatment once the patient reaches maturity. To best preserve the bony site for subsequent implant placement, it was decided to orthodontically submerge the endodontically treated root. A Carolina bridge was selected as the best interim prosthesis. The occlusal relationship is favorable,

and sufficient crown length of the abutment teeth exists.

At the first appointment, shade selection is determined, taking care that the teeth are not allowed to dehydrate prior to this assessment. An elastomeric impression is made of the anterior segment from which a working cast is generated. An impression of the opposing arch is made, as well as a bite registration.

An all-porcelain pontic is fabricated of feldspathic porcelain by the laboratory (Figure 5B). Feldspathic porcelain is preferred to other ceramic materials because of the ease with which it can be effectively etched with hydrofluoric acid. A modified ridge lap pontic tip design is used for the Carolina bridge. The proximal surfaces of the pontic are etched with hydrofluoric acid to afford a highly retentive surface for adhesive bonding.<sup>21,22</sup> It is important that all surfaces to be bonded and included in the resin composite connector area are effectively etched. It is recommended that the surfaces to be etched extend the full length of the proximal surfaces incisogingivally and extend onto the lingual surface of the pontic at least to the position of the lingual line angle to ensure sufficient surface area for bonding. A positioning stent or index is fabricated from polyvinylsiloxane to facilitate positioning and bonding of the Carolina bridge at the delivery appointment (see Figure 5B).

At the second appointment, the involved abutment teeth are first cleaned with flour of pumice in a prophylaxis cup administered at slow speed using a prophylaxis angle hand-piece. The teeth are then thoroughly rinsed, and the area is isolated with bilateral cotton rolls. A 2 × 2-inch gauze is placed across the patient's mouth to prevent swallowing or aspiration of the pontic during try-in and cementation. Care must be taken not to allow the teeth to dehydrate prior to shade assessment.

The pontic is carefully trial positioned to assess the accuracy of the shade and the adaptation of the pontic to the residual ridge (Figure 5C). Once the accuracy of the shade and fit has been verified intraorally, the pontic is readied for cementation. If any contamination of the etched proximal surfaces of the porcelain pontic occurs during try-in, these surfaces should be cleaned by applying phosphoric acid briefly (a few seconds), followed by thorough rinsing and drying of the pontic. A silane coupling agent is placed on the etched proximal surfaces of the porcelain pontic to improve the bond strength.

Preparation of the abutment teeth consists simply of light roughening of the proximal surfaces with a coarse, flame-shaped diamond stone (Figure 5D). Roughening removes the outer fluoride-rich layer of enamel that is more imper-

vious to acid-etching and increases the surface area for bonding, thereby improving the bond strength of the resin connector to the enamel surfaces of the abutment teeth. The enamel of the proximal surfaces is acid etched using a 30 to 35% phosphoric acid etching gel for a minimum of 15 seconds (Figure 5E). Once etched, the proximal surfaces must be kept clean and dry to ensure optimal bonding.

At this point, the pontic is ready for bonding into the edentulous space. Adhesive resin is placed on the etched surfaces of the abutment teeth and porcelain pontic and is cured for 20 seconds (Figure 5F and G). A small amount of resin composite is applied to the proximal surfaces of the pontic (Figure 5H). A hybrid resin composite is recommended for the strength of the connectors. To prevent premature curing of the resin composite connectors during positioning, it is recommended that the operatory light be turned away slightly to avert direct illumination during the bonding sequence.

Using the polyvinylsiloxane index, the pontic is positioned in the edentulous space. Excess resin composite is removed with a resin composite instrument or an explorer (Figure 5I). The facial embrasures are defined, and the gingival embrasures are shaped to ensure that they are open to allow access for cleaning. The lingual

embrasures are not defined but rather are bulked to strengthen the resin composite connector. The resin composite in each interproximal connector area is cured with a light source directed from both facial and lingual directions for a minimum time of 20 seconds each to ensure complete maximal polymerization (Figure 5J). Additional resin composite is added and cured in any areas deemed deficient in contour. As noted earlier, the lingual contour of each resin composite connector should be continuous mesiodistally from the line angle of each abutment tooth across to the respective line angles of the porcelain pontic to maximize the cross-sectional diameter of the connectors and achieve optimal strength.

The final contours of the resin composite connectors are achieved using appropriate finishing burs. A series of abrasive points and cups are used to finish and polish the resin composite connectors. The occlusion is checked and adjusted to ensure that only minimal centric or functional contact is present.

The patient is instructed in proper oral hygiene techniques, including the correct use of a floss threader to access the underside of the pontic (Figure 5K). The patient (and/or the patient's parents) is once again reminded to avoid biting hard foods or objects to prevent fracture of connector areas. Also, as for all bonded

bridges, it is an important part of informed consent that the patient (and/or the patient's parents) once more be informed of the possibility of swallowing or aspiration of the pontic if it were totally dislodged.

This consent should be given in writing, with a signature of acknowledgment obtained from the patient or the patient's parent if the patient is a minor. The completed Carolina bridge is seen in Figure 5L and M.

REPAIR OF THE RESIN COMPOSITE CONNECTOR

Although infrequently, patients will occasionally present with a fractured resin composite connector. Usually, a fracture of a resin com-

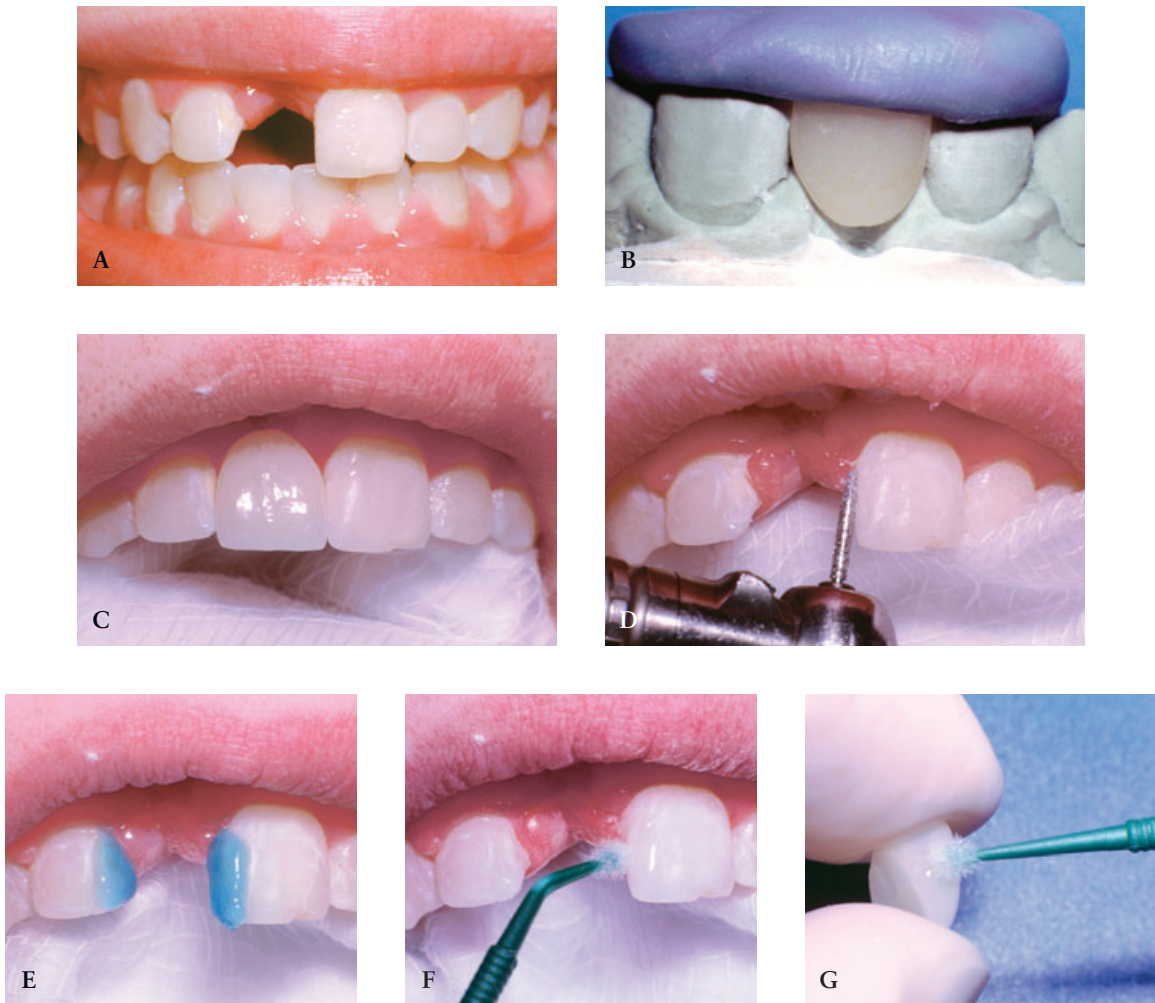


Figure 5. A, Patient with a traumatically missing maxillary central incisor. B, Porcelain pontic viewed on a model with a polyvinylsiloxane index. C, Pontic being tried in place prior to bonding. Note protective gauze in place. D, Light roughening of the enamel proximal surfaces of the abutment teeth with a coarse diamond. E, Acid-etching of the involved proximal surfaces with phosphoric acid. F and G, A light-cured resin bonding agent is applied to both the proximal surfaces of the abutment teeth and the pontic and cured prior to bonding of the pontic. (continued on next page)

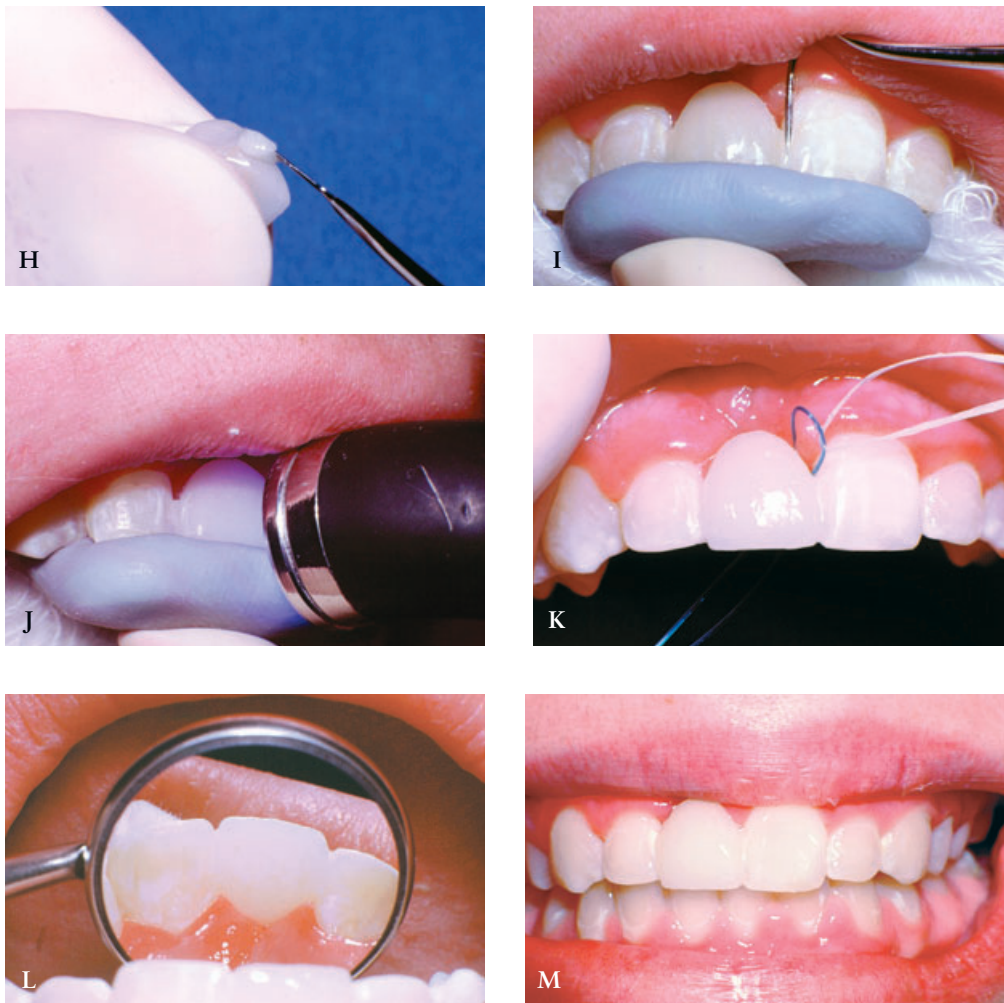


posite connector occurs when a patient inadvertently bites on a hard food or object. It is very rare that both connectors would fracture even from this type of insult. Almost always, patients are imme-

diately aware if a resin composite connector fractures.

As seen in Figure 6, a patient presented with a fractured resin composite connector that resulted from

biting a hard candy. The first step in repair of the resin composite connector is to use an ultrathin, tapered diamond instrument to remove the existing resin composite from the abutment tooth and the



*Figure 5 (continued). H, Resin composite is applied to the proximal surfaces of the pontic in preparation for bonding. I and J, The porcelain pontic is positioned using a PVS index, and the resin composite connectors are shaped and light-cured. K, The patient is instructed regarding the proper use of a floss threader to facilitate regular cleaning of the area. L and M, Lingual and facial views of the completed all-porcelain bonded pontic.*

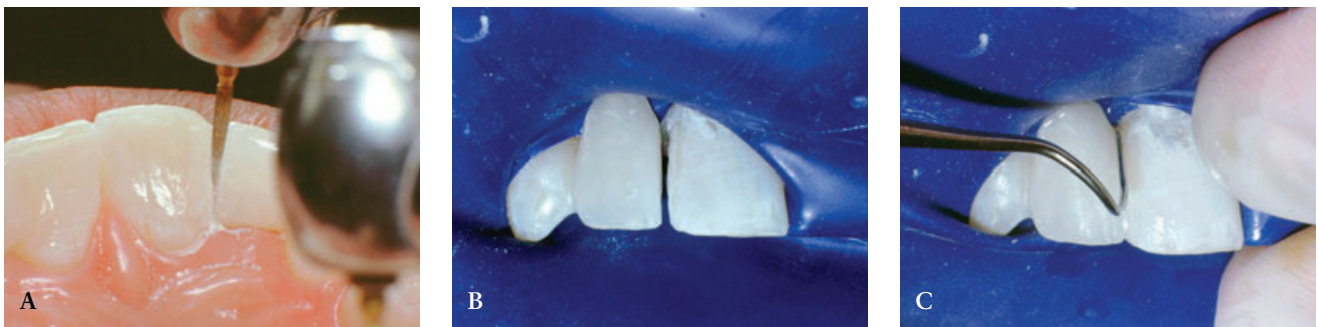
porcelain pontic (see Figure 6A). If needed for adequate access, always open the connector at the expense of the porcelain pontic. Never remove tooth structure to gain access for repair of the resin composite connector. The remnants of the resin composite connector must be removed to expose porcelain on the pontic and enamel on the abutment tooth to allow proper etching and bonding.

Once the connector area is free of resin composite remnants and the interproximal area is open, a rubber dam is placed using the open contact for access (see Figure 6B). To ensure an optimal gingival seal during etching and bonding, the rubber dam is ligated. A Mylar strip is contoured and placed interproximally

to protect the enamel surfaces of the abutment tooth during etching procedures of the porcelain pontic. The proximal surfaces of the porcelain pontic are etched using a 9.6% buffered hydrofluoric acid gel applied for 2 minutes or as recommended by the manufacturer. Care must be taken to extend application of the etching gel just beyond the lingual line angle of the pontic to achieve sufficient surface area for bonding of the resin composite connector. Following the timed application of the porcelain etchant, the surfaces are thoroughly rinsed with water for 5 to 10 seconds. The etched porcelain surfaces are thoroughly dried. A lightly frosted appearance should be evident. While maintaining isolation of the natural tooth abutment with a

Mylar strip, a silane coupling agent can be applied and dried according to the manufacturer's instructions.

Following etching of the porcelain surfaces, the enamel surfaces of the abutment tooth are acid etched with a 30 to 35% phosphoric acid etching gel for a minimum of 15 seconds. Thereafter, the enamel surfaces are rinsed for 5 to 10 seconds with a steady stream of water, followed by air drying. Adhesive resin is placed on the etched surfaces of the porcelain pontic and the abutment tooth and is cured for 20 seconds. An appropriate shade of resin composite is inserted into the connector area and shaped using an explorer or resin composite instrument, as noted previously (see Figure 6C).



*Figure 6. A and B, A fractured resin composite connector is removed with an ultrasonic, flame-shaped diamond instrument, exposing enamel and porcelain proximal surfaces. C, After proper etching of proximal surfaces (porcelain with 9.6% buffered hydrofluoric acid and enamel with 35% phosphoric acid), a new resin composite connector is generated. D, Immediate postoperative view of a repaired all-porcelain bonded bridge. Note the dehydration line consistent with the isolation level of the rubber dam.*

The final contours of the resin composite connectors are achieved using suitable finishing burs. A series of abrasive points and cups are used to finish and polish the resin composite connectors. The occlusion should be assessed to ensure that no heavy centric or functional contact exists on the newly placed resin composite connector. Again, the patient should be reminded to avoid biting hard foods or objects. The final result can be seen in Figure 6D.

Resin composite connectors will periodically need surfacing, replacement, or repair owing to staining, wear, or fracture (Figure 7). However, unlike other types of bonded bridges that are inherently invasive, Carolina bridges use simple composite connectors that can be easily repaired. Additional strengthening of connector areas can be achieved through the use of a fiber reinforcing material, such as Ribbond THM (Ribbond, Inc., Seattle, WA, USA), if the occlusion allows. However, additional reinforcement of this type is rarely needed if proper case selection has occurred and sufficiently large connectors have been achieved for optimal strength.

#### SUMMARY

The Carolina bridge is a novel all-porcelain bonded prosthesis that can serve as an outstanding interim prosthesis for the replacement of single anterior incisors. As noted repeatedly, the absolute key to suc-

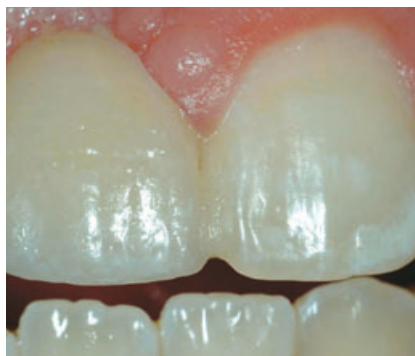

Figure 7. Typical all-porcelain bonded bridge replacing a maxillary right central incisor seen after 4 years, 2 months of service. Stained areas of the resin composite connector typically require resurfacing or replacement.

cess is the availability of adequate surface area for bonding.

#### DISCLOSURE AND ACKNOWLEDGMENT

The author does not have any financial interest in the companies whose materials are discussed in this article.

The author wishes to acknowledge the outstanding work of Mr. Daniel Materdomini of da Vinci Dental Studios and Mr. Andre Theberge of Drake Precision Dental Lab for their technical expertise in the fabrication of these prostheses.

#### REFERENCES

1. Rochette AL. Attachment of a splint to enamel of lower anterior teeth. *J Prosthet Dent* 1973;30:418.
2. Heymann HO. Resin-retained bridges: the porcelain-fused-to-metal winged pontic. *Gen Dent* 1984;32:203-8.
3. Livaditis G. Cast metal resin-bonded retainers for posterior tooth. *J Am Dent Assoc* 1980;101:926.

4. Livaditis G, Thompson VP. Etched castings: an improved retentive mechanism for resin-bonded retainers. *J Prosthet Dent* 1982;47:52.
5. Hansson O. The silicoater technique for resin-bonded prostheses: clinical and laboratory procedures. *Quintessence Int* 1989;20:85-99.
6. Matsumura H, Nakabayashi N. Adhesive 4-META/MMA-TBB opaque resin with poly (methyl methacrylate)-coated titanium dioxide. *J Dent Res* 1988;67:29-32.
7. Ibsen RL, Strassler HE. An innovative method for fixed anterior tooth replacement utilizing porcelain veneers. *Quintessence Int* 1986;17:455-9.
8. Schaffer JL. All-porcelain anterior fixed partial denture: a preliminary report. *J Prosthet Dent* 1988;59:669-71.
9. Denissen HW, Gardner FB, Wijnhoff GF, et al. All porcelain anterior veneer bridges. *J Esthet Dent* 1990;2:22-7.
10. Moore DL, Demke R, Eick JD, Sigler TJ. Retentive strength of anterior etched porcelain bridges attached with resin composite resin: an in vitro comparison of attachment techniques. *Quintessence Int* 1989;20:629-36.
11. Denissen HW, Wijnhoff GF, Veldhuis AA, Kalk W. Five-year study of all porcelain veneer fixed partial dentures. *J Prosthet Dent* 1993;69:464-8.
12. Hornbrook DS. Anterior tooth replacement using a two-component resin-bonded bridge. *Compend Contin Educ Dent* 1993;14:52-9.
13. Leal FR, Cobb DS, Denehy GE, Margeas RC. A conservative aesthetic solution for a single anterior edentulous space: case report and one-year follow-up. *Pract Proced Aesthet Dent* 2001;13:635-41.
14. Kern M, Knode H, Strubb JR. The all-porcelain, resin-bonded bridge. *Quintessence Int* 1991;22:257-62.
15. Trushkowsky RD. Replacement of congenitally missing lateral incisors with ceramic resin-bonded fixed partial dentures. *J Prosthet Dent* 1995;73:12-6.
16. Pospiech P, Rammelsberg P, Unsold F. A new design for all-ceramic resin-bonded fixed partial dentures. *Quintessence Int* 1996;27:753-8.

17. Antonson DE. Immediate temporary bridge using an extracted tooth. *Dent Surv* 1980;56:22-5.
18. Heymann HO. Resin-retained bridges: the natural tooth pontic. *Gen Dent* 1983;31:479-82.
19. Heymann HO. Resin-retained bridges: the acrylic denture tooth pontic. *Gen Dent* 1984;32:113-7.
20. Heymann HO. Additional conservative esthetic procedures. In: Roberson TM, editor. *The art and science of operative dentistry*. 4th ed. St. Louis: CV Mosby Co; 2001. p. 592-649.
21. Calamia JR. Etched porcelain facial veneers: a new treatment modality based on scientific and clinical evidence. *N Y J Dent* 1983;53:255-9.
22. Stangel I, Nathanson D, Hsu CS. Shear strength of the composite bond to etched porcelain. *J Dent Res* 1987;66:1460-5.

*Reprint requests: Harald O. Heymann, DDS, Med, Department of Operative Dentistry, UNC School of Dentistry, 302 Brauer Hall, Chapel Hill, NC, USA 27599-7450; e-mail: Harald\_Heymann@dentistry.unc.edu*  
©2006 Blackwell Publishing, Inc.

## COMMENTARY

### THE CAROLINA BRIDGE: A NOVEL INTERIM ALL-PORCELAIN BONDED PROSTHESIS

W. Dan Sneed, DMD, MAT, MHS\*

Adhesives have certainly changed the way we practice dentistry. Macromechanical resistance and retentive features have historically been a hallmark of quality restorative dentistry. Even today, it is certainly wise to incorporate mechanical design along with adhesives. This article, however, presents a very viable alternative to the traditional grooves, pins, and slots to retain a single-tooth pontic.

The author begins with a thorough review of the pertinent literature. He describes the various methods of fabricating conservative, single-tooth, fixed partial dentures, and most of these require some significant preparation of the abutment teeth. The author is intimately aware of his options, as well as the advantages and disadvantages of each. With that understanding, he then proposes a truly adhesive bridge that is totally reversible. At first read, this approach may seem futile. Many dentists have tried “gluing” pontics between two abutment teeth only to see them quickly fail. The difference here is the dentist’s clear understanding of the indications for and the limitations of this technique. There is also an understanding of occlusion and material and adhesive dynamics.

For this procedure, the author selects only patients who meet a defined set of criteria, and those patients understand what to expect. Then feldspathic porcelain is used because it, unlike some other ceramics, can be etched with hydrofluoric acid. The application of a silane then ensures that the adhesive interface is stronger than the cohesive strength of either the porcelain or the composite.<sup>1-3</sup> The enamel is lightly abraded with a diamond to enhance an already tenacious enamel bond.<sup>4</sup> A hybrid composite is selected because of its strength. The connector areas must be of a certain width and length, and again and again, the author makes informed judgments.

The true message of this article is not just another technique but a process of problem solving based on knowledge and judgment. If we all approached restorative dentistry this way, with an informed patient and a knowledgeable dentist, surprises would be few and far between and success would be routine.

#### REFERENCES

1. Guler AU, Yilmaz F, Ural C, Guler E. Evaluation of 24-hour shear bond strength of resin composite to porcelain according to surface treatment. *Int J Prosthodont* 2005;18:156-60.
2. Knight JS, Homes JR, Bradford H, Lawson C. Shear bond strength of composite bonded to porcelain using porcelain repair systems. *Am J Dent* 2003;16:252-4.
3. Barghi N. To silanate or not to silanate: making a clinical decision. *Compend Contin Educ Dent* 2000;21:659-62.
4. Schneider PM, Messer LB, Douglas WH. The effect of surface reduction in vitro on the bonding of composite resin to permanent human enamel. *J Dent Res* 1981;60:895-900.

\*Professor and chair, Department of General Dentistry, MUSC College of Dental Medicine, Charleston, SC, USA